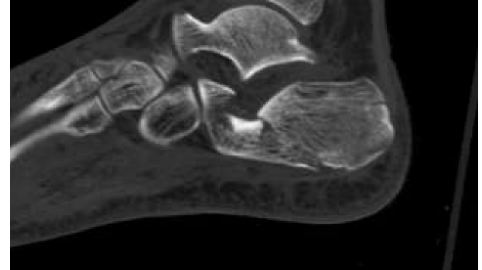
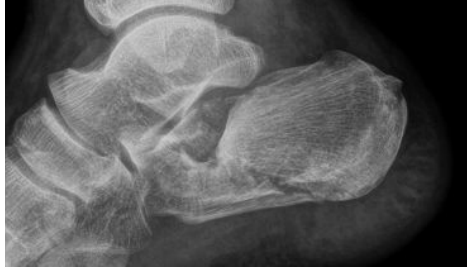
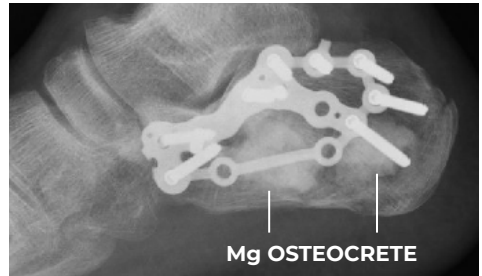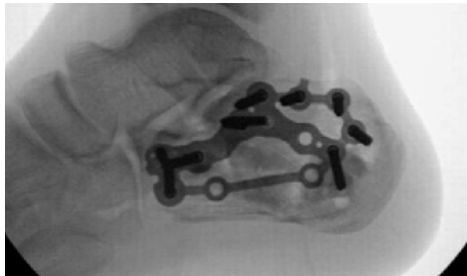Thomas L. Hand, MD- UT Health San Antonio

36 YO M, fall from roof.
Comminuted calcaneal fracture with impaction of the posterior facet.

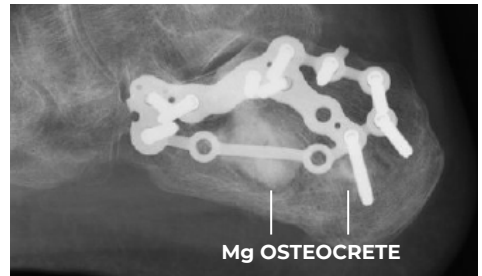
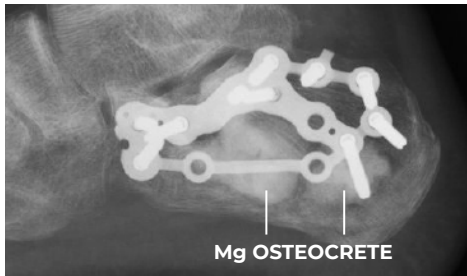


Lateral surgical approach.
Elevation of impacted posterior facet followed by plate and screw fixation.

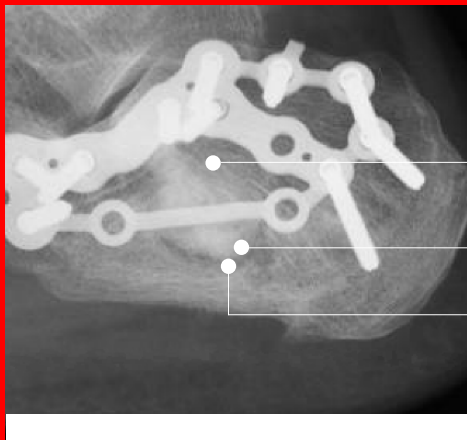10cc **Mg OSTEOCRETE** was used to fill the residual bone void.



Mg OSTEOCRETE resorption visualized within 4 months as demonstrated by decreased opacity of the bone graft and blurring of the peripheral margins.



Resorption After 7 Months



Marked decreased opacity of bone graft posteriorly with bone trabeculae formation noted throughout the graft area.

Residual **Mg OSTEOCRETE** remains anteriorly, but opacity of bone graft area with trabeculae formation is decreased.

Lateral cortex is well-healed.